



EMERGENCY HEART SURGERY FOR MYXOMA IN PREGNANT WOMEN: PERIOPERATIVE MANAGEMENT STRATEGY

N.Chikh ; D Benali Amar; N.Chibani; D Elkebir

Auteur n1chikh@yahoo.f

Abstract

Myxoma is extremely rare during pregnancy, the surgical resection is required.

Cardiac surgery with cardiopulmonary bypass (CPBP) during pregnancy is a high-risk situation for both mother and fetus. It remains exceptional performed mainly in the context of the emergency. The authors report the case of cardiac surgery with (CPBP) in a young woman of 24 years pregnant with a progressive pregnancy of 22 weeks with a myxoma of the left atrium threatening. Per- and post-operative monitoring was performed by the usual monitoring in this type of surgery associated with tococardiograph. CPBP was performed in normothermia with a high flow rate for blood pressure of at least 70 mmhg, hematocrit, blood sugar and acid-base balance were maintained within the correct limits. The CPBP was short-lived and the bypass exit was simple without inotropics. The procedures were simple with a good evolution for the mother and the fetus.

Keywords: cardiac surgery/ cardiopulmonary baypass/ pregnancy/ myxoma

INTRODUCTION:

Myxoma is extremely rare during pregnancy (1), it is associated with a high risk of cardiogenic shock and thrombo-embolic(2). The surgical resection is required. Cardiac surgery with cardiopulmonary bypass (CPBP) during pregnancy is a high-risk situation for both the mother and the fetus; it is still exceptional, carried out mainly in the context of the emergency. Maternal mortality is currently 0.5-6% (3-5) of maternal deaths. The mean fetal morbidity-mortality for CPBP is 20-30% (4, 6, 7). Anaesthetic management must ensure the safety of the mother while allowing fetal survival in the best possible conditions. This situation represents a challenge for the team (surgeons, cardiologists, anaesthesiologists, and obstetricians). The objective of this article is to illustrate the difficulties encountered in this field, as well as the strategy of taking anesthesia and intensive care.

OBSERVATION :

She is a 24-year-old parturient, having a Progressive Pregnancy of 22 Weeks amenorrhea, first gesture and without particular surgical ant medical history. Admitted in an emergency for the surgical management of a threatening intra-cardiac (left intra-ear) mass. The beginning of the symptomatology seems to be traced back to the beginning of her pregnancy by progressively worsening exercise dyspnea and palpitations that pushed the parturient to consult in cardiology.

During her admission :

The patient had a good overall condition, she described dyspnea (NYHA III), Hemodynamic was correct (115/65) as well as oxygen saturation (SPO2 at 97%). Trans-thoracic echocardiography (TTE) objectified: a mass in the Left Atrium, spherical, homogeneous, pedicular, mobile, measuring (45 /65mm) that prolapses in diastole in the left ventricle (LV), suspected intracardiac myxoma (Figure 1). The rest of the ultrasound assessment returns to: a good LV function an ejection fraction (EF) at 67%, no cavity dilation, no valve abnormality and normal pulmonary pressure.

The other tests (clinical, gynecological and biological) did not reveal any abnormalities. Given the threatening nature of the mass, as well as the high thromboembolic risk, emergency intervention was decided.

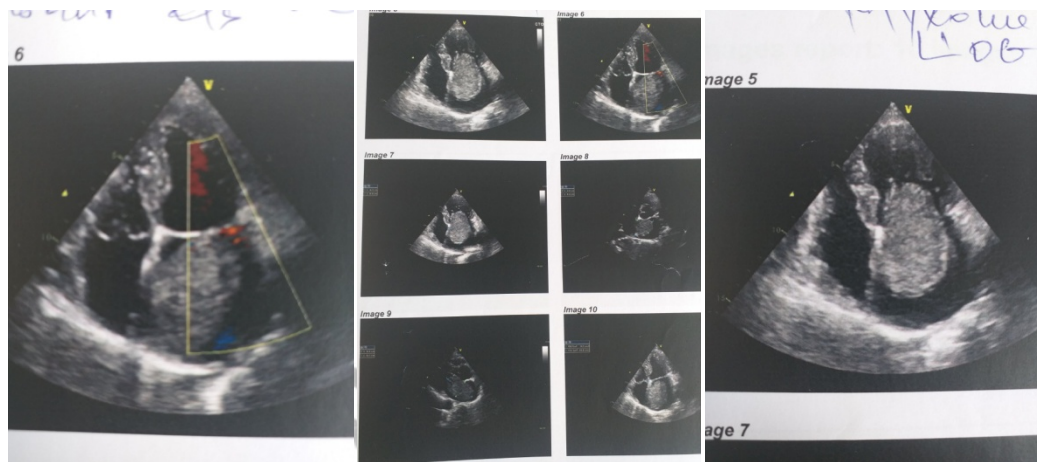


Figure 1: A. 4-chamber apical section showing hyperechogenic formation at almost the entire left atrium

In operating room

The patient was placed in slight left lateral position, the procedure was performed under General Anesthesia, respecting the physiological changes related to pregnancy and hemodynamic changes related to his heart disease. Protocol (Etomidate: 0.3mg/kg single dose, Fentanyl: 8µg/kg and Norcuron: 6mg). Maintain anaesthesia with sevoflurane and fentanyl in auto-pulsed syringe. The patient received standard non-invasive and invasive monitoring (intraarterial catheter and central venous pathway, oesophageal temperature ...) and monitoring of uterine contractions (UC) and fetal heart rate (FCR) by a Tococardiograph with the help of gynecologists.

The complete resection of the mass was done under cardiopulmonary bypass (CPBP) with cardiac arrest with aortic clamping and myocardial protection by crystalloid cardioplegia, a pulse-free flow (3.6 l/min/m²), infusion pressure was (65-77mmhg), in normothermia (T°C:36.4°C), Ht at 30% and Ph 7.43. Anticoagulation by heparin 3mg/Kg

A few minutes after the departure of the CPBP, the patient presented uterine contractions (UC) with fetal tachycardia (25 UC, 228 BPM), then soon rapidly tocolysis by an injection of Nicardipine (dilution 0.2mg/ml) has reduced the UC threshold to 6 and the FCR to 127 Beats per Minute.

After aortic unclamping, a spontaneous defibrillation of the heart and easy (CPBP) output without inotropic drugs. Heparin was antagonized by protamine. The total duration of CPBP and Aortic clamping was 29 and 21 min respectively.

In intensive care unit, in addition to the usual monitoring of the patient, the parturient received continuous monitoring of the pregnancy by tococardiograph and ultrasound control by the gynecologist. Hemodynamic parameters were correct without inotropics, good oxygenation parameters, correct temperature and acceptable biological balance as well (Ht 33%; Hb 11; glycaemia 1.55g/l, Ph 7.34) normal ionogram.

The postoperative aftermath was simple. Feto-maternal vital functions remained stable. The duration of postoperative ventilation was 3 hours. Post-operative pain was controlled by paracetamol every 6 hours and diclofenac in continuous infusion over 8 hours once. At day1 Post-operative, the parturient was dedrained, transferred to the cardiac surgery department after a clinical examination and ultrasound done by the gynecologist who confirmed the viability of the fetus and the absence of hemorrhagic complications for the mother.

Anatomo-pathological result was in favor of **myxoma**, as shown in Figure 2

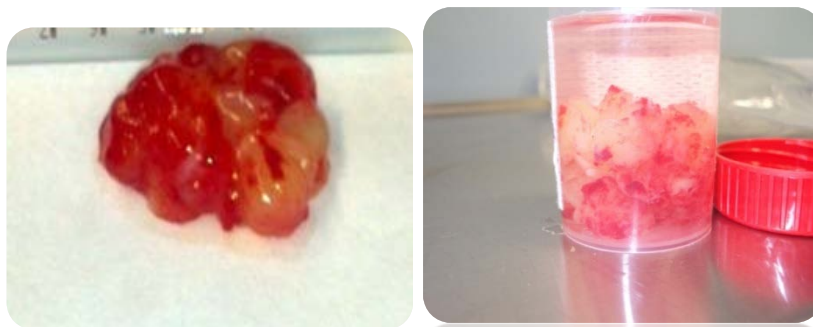

Figure 2: Myxoma after removal. It was huge

The evolution was good and the patient was transferred to the maternity ward after 15 days for surveillance and follow-up

Pregnancy was carried to term and low-birth of a Newborn living well, by vaginal delivery, Apgar score was correct. The child's psychomotor development was normal. On the cardiac side, the patient received periodic clinical and ultrasound supervision for two years, without recurrence of the tumor.

DISCUSSION:

Cardiac myxomas are the most common primary cardiac tumors, accounting for 50% of cases. In 60%-80% of cases, myxomas are found in the left atrium (2, 8, 9). It is extremely rare during pregnancy, only 51 reported cases in the literature(1). The treatment of these tumors remains surgical ablation. In 10 years we have operated on about 45 cases of myxoma in our department (4 to 5 cases for 250 interventions), including one case during pregnancy. Dyspnea and palpitations are the most common symptoms in these patients. these are the most frequent symptoms in this type of pathology (5). Anesthesia for cardiac surgery under CPBP in pregnant women is a challenge for the team, due to the physiological changes in pregnancy, heart disease, the urgency of surgery and the consequences of CPBP on the mother and fetus(10, 11). The authors stress the importance of discussing with the patient the risk of the operation for her and her baby (12) . Our patient was aware of the risk, and she accepted to do so urgently. Studies highlight the importance of respecting anesthetic imperatives in pregnant women (prevention of the risk of hypoxemia, inhalation: rapid-sequence induction, sellick operation, preoxygenation, a facility to avoid aorto-cave syndrome, to ensure

hemodynamic stability, etc.) and compliance with the recommendations for the CPBP to know(13-15)

- ✓ Maintain correct perfusion pressures
 - ✓ CEC soft start
 - ✓ High flow 3l/mn/m2, PAM>70mmhg and pulsed flow
- ✓ A normothermia (T°35-37)
- ✓ Ht >28% and Hb 9g/dl, normal PH
- ✓ The shortest possible clamping and CEC time
- ✓ Fetal Monitoring

Normothermia is mandatory because these variations lead to contractions in the uterus that cause premature birth(13). Normal maintenance of other physiological parameters such as blood sugar and gas is required. The Tococardiograph has become an essential tool for the continuous monitoring of fetal activity in recent years (8, 12, 13). The risk factors for fetal-maternal morbidity-mortality are the degree of urgency, re-intervention, the severity of heart disease, time of CPBP and the end of pregnancy(16, 17).

In our observation, pregnancy was far from childbirth, cardiac functions were not impaired, but the presence of a tumor occupying almost the entire atrium and resulting in a vital risk to the mother makes surgical removal extremely urgent. The decision to operate the patient was made in a collegial way (cardiologist, obstetrician gynecologist, Anesthesiologist and cardiac surgeon), dictated by the risk of maternal complications of the pathology. The parturient was informed about the high risk of the surgery. The clamping and CPBP time were short-lived (21mn and 29mn). According to the literature, the good fetal-maternal prognosis of this type of intervention is explained by the short time of the CPBP (15). The recommendations of CPBP were met, except for the pulsed flow that was not available on our CPBP device. The occurrence of uterine contractions and fetal suffering at the start of CPBP is probably secondary to variations in the flow rate and also to the recuperation by surgeon cold cardioplegia. Post-operative hemodynamic stability, optimization of oxygenation, normalization of biological parameters and continued close monitoring of mother and child are necessary.

CONCLUSION:

The occurrence of myxoma on a pregnancy is a serious pathology that can put the maternal and fetal prognosis at risk. Management involves a multidisciplinary collaboration that is the magic key to quality perioperative management of cardiac surgery in pregnant women. This optimal strategy can certainly improve the vital prognosis of the mother and her child by respecting the anesthetic imperatives related to pregnancy and heart disease, as well as the recommendations related to the CPBP.

BIBLIOGRAPHY :

1. Alexis A, Origer P, Hacquebard JP, De Cannière D, Germa O, Vandenbossche JL, et al. Anesthetic Management of a Voluminous Left Atrial Myxoma Resection in a 19 Weeks Pregnant with Atypical Clinical Presentation: Case Rep Anesthesiol. 2019 Dec 12;2019:4181502. doi: 10.1155/2019/4181502. eCollection 2019.
2. Yuan SM, Yan SL, Wu N. Unusual aspects of cardiac myxoma. Anatol J Cardiol. 2017;17(3):241-7.
3. Parry AJ, Westaby S. Cardiopulmonary bypass during pregnancy. The Annals of thoracic surgery. 1996;61(6):1865-9.

4. Weiss BM, von Segesser LK, Alon E, Seifert B, Turina MI. Outcome of cardiovascular surgery and pregnancy: a systematic review of the period 1984-1996. *American journal of obstetrics and gynecology*. 1998;179(6):1643-53.
5. Yuan S-M. Indications for cardiopulmonary bypass during pregnancy and impact on fetal outcomes. *Geburtshilfe und Frauenheilkunde*. 2014;74(1):55.
6. Regitz-Zagrosek V, Roos-Hesselink JW, Bauersachs J, Blomström-Lundqvist C, Cifková R, De Bonis M, et al. 2018 ESC Guidelines for the management of cardiovascular diseases during pregnancy: The Task Force for the Management of Cardiovascular Diseases during Pregnancy of the European Society of Cardiology (ESC). *European Heart Journal*. 2018;39(34):3165-241.
7. Chandrasekhar S, Cook CR, Collard CD. Cardiac Surgery in the Parturient. *Anesthesia & Analgesia*. 2009;108(3):777-85.
8. Agarwal R, Bhattacharya P, Bhattacharya L, Jain R. Pregnancy and cardiopulmonary bypass. *Indian J Anaesth*. 2004;48(4):259-63.
9. Aamani Jupalli , Ateeq Mubarik , Arshad Muhammad Iqbal , Mowaffak Atfeh , Muddassir S. Atrial Myxoma Presenting as Positional Vertigo: A Case Report
Cureus 11(6): e4884. (June 11, 2019).
10. Saeed M. R. Elassy M, PhD, , Ashraf A. Elmidany M, PhD, , and Hatem Y. Elbawab M, PhD. Urgent Cardiac Surgery During Pregnancy: A Continuous Challenge. *Ann Thorac Surg* 2014; 97:1624-9. 2014.
11. Salazar E, Espinola N, Molina FJ, Reyes A, Barragán R. Heart surgery with cardiopulmonary bypass in pregnant women. *Archivos de Cardiología de Mexico*. 2001;71(1):20-7.
12. STRICKLAND RA, OLIVER Jr WC, CHANTIGIAN RC, NEY JA, DANIELSON GK, editors. *Anesthesia, cardiopulmonary bypass, and the pregnant patient*. Mayo Clinic Proceedings; 1991: Elsevier.
13. Kapoor M. Cardiopulmonary bypass in pregnancy. *Annals of Cardiac Anaesthesia*. 2014;17(1):33-9.
14. CHASSOT P-G, THORIN D, NEFF R, KERN C. *grossesse et chirurgie cardiaque • Précis d'anesthésie cardiaque* 2018.
15. John AS, Gurley F, Schaff HV, Warnes CA, Phillips SD, Arendt KW, et al. Cardiopulmonary bypass during pregnancy. *The Annals of thoracic surgery*. 2011;91(4):1191-6.
16. Arnoni RT, Arnoni AS, Bonini RC, de Almeida AF, Neto CA, Dinkhuysen JJ, et al. Risk factors associated with cardiac surgery during pregnancy. *Ann Thorac Surg*. 2003;76(5):1605-8.
17. Ávila WS, Gouveia A, Pomerantzeff P, Bortolotto M, Grinberg M, Stolf N, et al. Maternal-fetal outcome and prognosis of cardiac surgery during pregnancy. *Arq Bras Cardiol*. 2009;93(1):9-14.